

Pneumonia cluster in tourists returning from Malaysia

Tamim Khawaja, Rovaniemi FI

- Group of five, four treated in LKS, 1 in Aurora
- Langawi, Malaysia 27.10.2007, Singapore 7.11,
Finland 11.11. First symptoms 12.11

- M54, HTA, lisinopril 20mg 1x1.

Cough 14.11, fever 16.11

- M57, DM2 diet, HTA, bisoprolol 10mg 1x1

Fever 17.11

- F46
- 12.11 sore throat, fatigue, 16.11 fever
- F54
- Tired, hosp 18.11->fever
- Male, treated in Aurora, HKI

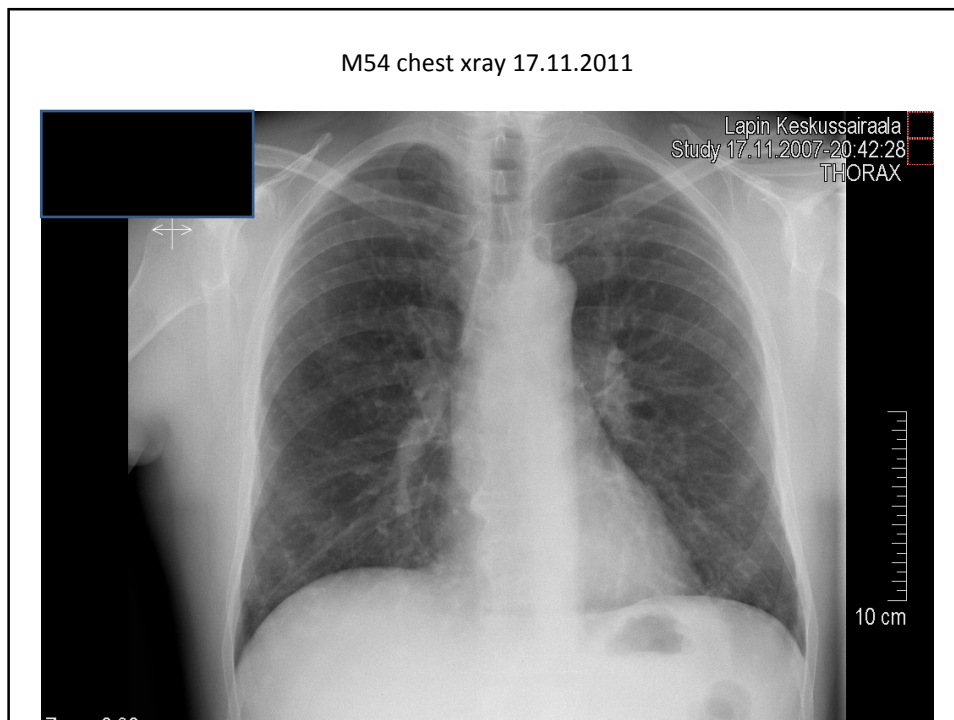
- Good hotel in the jungle
- Monkeys visited rooms, ate fruits
- Swam in swimming pools, ocean.
- No milk products
- No visiting people's homes
- Bare-foot walking
- Building work going on at other parts of the hotel
- Moved as a group

- Bats flying around the hotel
- No caves
- Visited a bird house/zoo c 3.11, parrots, fans present.
- Rode an elephant
- No other tourists of the same group (hotel) got sick according to the Swedish guide.

M54

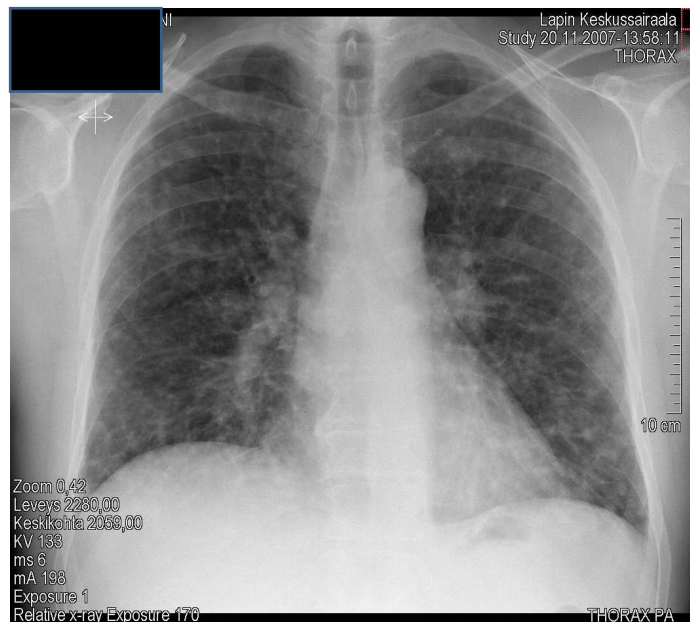
- Hep A+B, Typhoid fever, polio, yellow fever, tetanus, JE, diphtheria vaccinations, no malaria prophylaxis.
- Few hours of diarrhea in Malaysia, otherwise healthy except for slight cough a couple of days after arrival
- Emergency clinic on 17.11
- 3 days of fatigue, dry unproductive cough
- Slight muscle pains
- Fever the previous night

- General condition good
- Fever c 39 C, BP 177/93, P105
- Chest X-ray diffuse infiltrates, next page
- Hb 144, Leuk 10,7, trom 267 (next day diff polymorphonuclear 71%, eos 4,5%, mono 10,5%, lymf 13%)
- CRP 231, ALAT 29, Afos 69, bil 7, Na 136 K 3,1 Krea 90
- Urine chemical analysis clean.
- cefuroksime 1,5gx3, Levofloxacin 500mg 1x1
- Cefuroxime->ceftriaxone 20.11
- Levofloxacin 500mgx2 po 22.11



- No fever after 19.11.
- Crp
 - 17.11 **231**
 - 19.11 **131**
 - 22.11 **119**
 - 24.11 **104**
- X-ray progresses, general condition of all patients remains excellent
- This patient alone develops a couple of skin lesions. Several hardened round elevations with red papule in the middle, upper chest and back

M54 20.11.2011



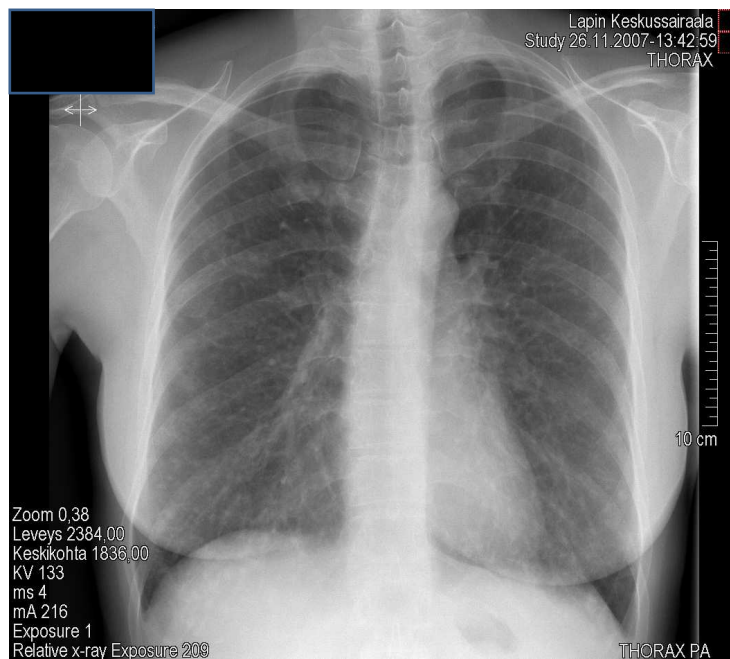
- Blood cultures negative
 - Urine E. coli and E. Faecalis
 - Malaria neg
 - chlamydia pn, dengue, legionella- leptospira, mycoplasma, rickettsia, orientia tsutsugamushi, toxoplasma, coxiella burnetii, brucella, burkholderia pseudomallei serology repeatedly negative
 - Anthrax culture from nasopharynx negative
 - TB negative
- Echo ok

- Chlamydia psittaci (CF) neg 22.11, not repeated
- M57 minimal Legionella titers and slight elevation on II sample, F46 similar finding
- Other patients had similar but even less severe symptoms, were hospitalised, headache, myalgia, slight chest pains, fever, dry unproductive cough. No significant serology, no cultures pos.

F46

- Fever 38C 16.11->
- Hosp 17.11.2011, xray clean
- CRP ad 115 on 17.11, leuk 8,9, trom 182, liver enzymes and krea ok.
- Bronchoscopy 28.11, no culture pos
- Symptoms lasted the longest, fatigue slight joint pains for a year, HRCT repeated 11/08

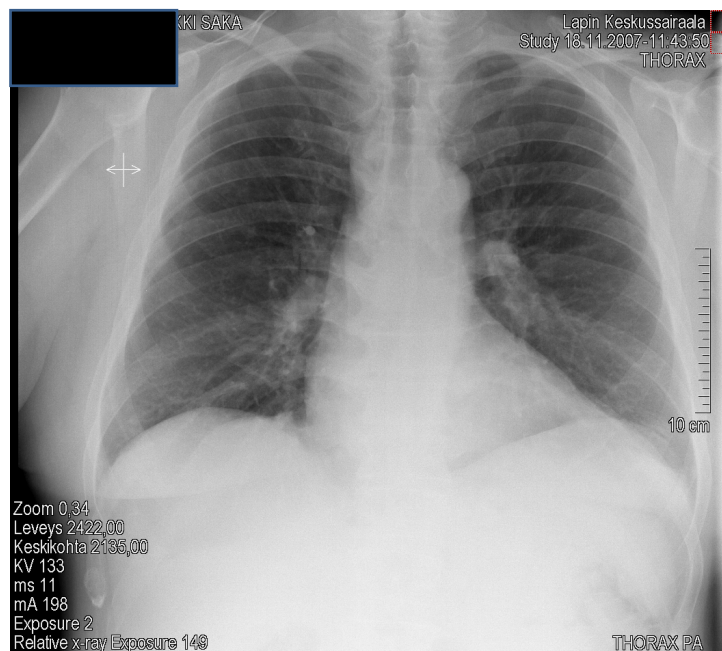
F46 26.11.2007

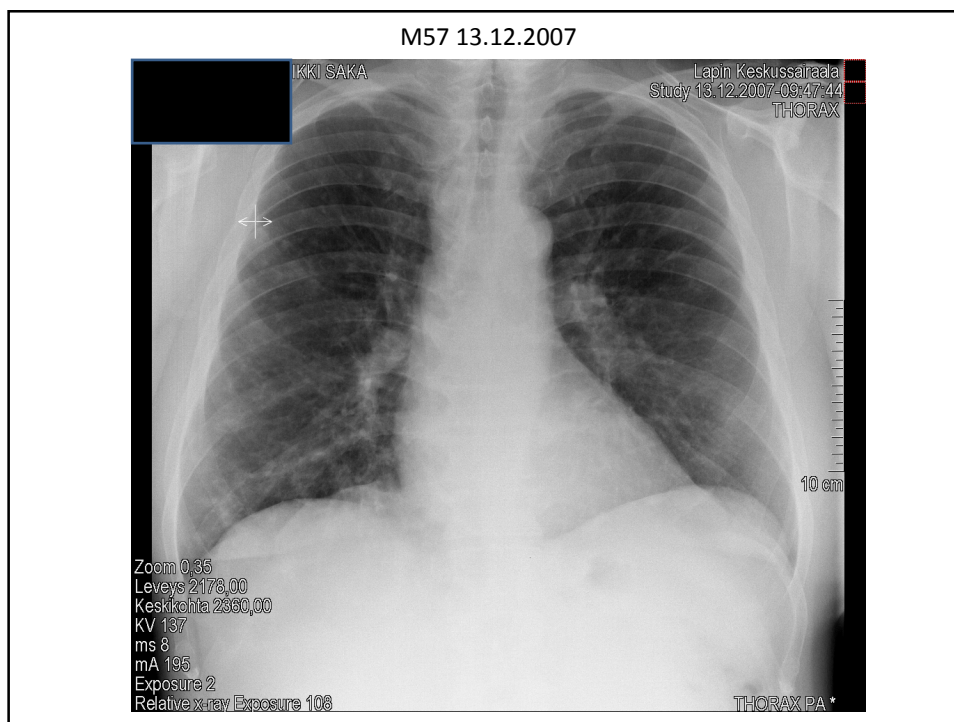


M57

- Fever 17.11, hosp 18.11
- CRP ad 116 on 19.11
- Again liver enz. Krea, NA, K norm, no leucosytosis.
- Discharged 23.11. Slight malaise continues for several months, some arthralgias.

M57 Xray 18.11

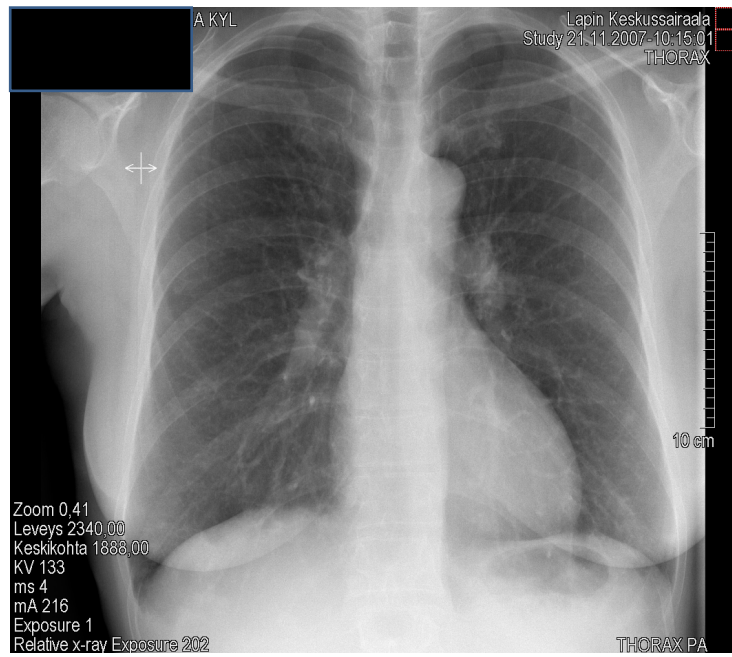




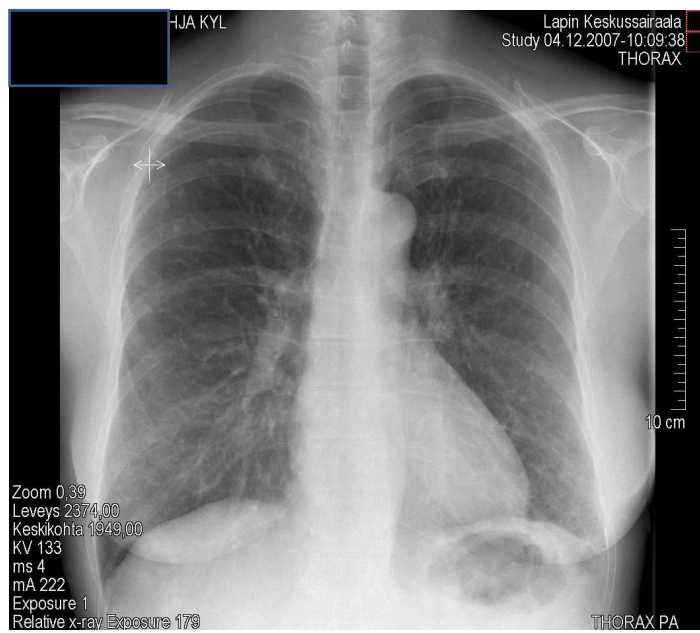
F53

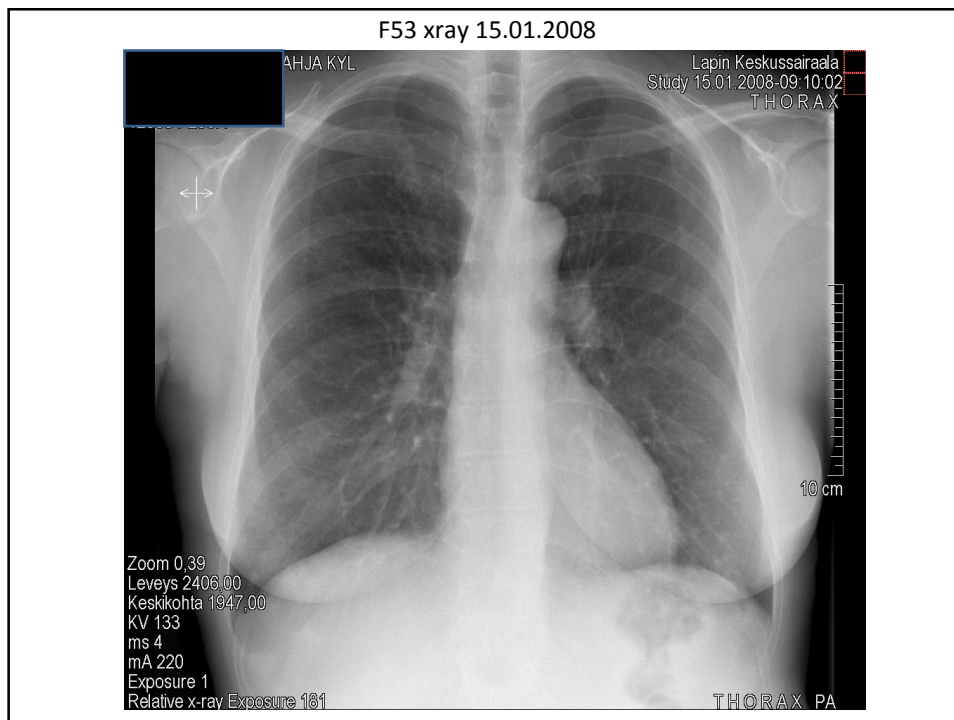
- Hospitalized on 18.11 after the others. No fever, just fatigue, xray clear on admission
- CRP 21 ->89 on 21.11 then declines
- Other lab ok, cultures neg.
- Slight fever 19-21.11 then ok.
- discharged 23.11. Slight fatigue for a couple of months. CRP 39 04.01.08 and 13 on 22.02.08

F53 21.11.07




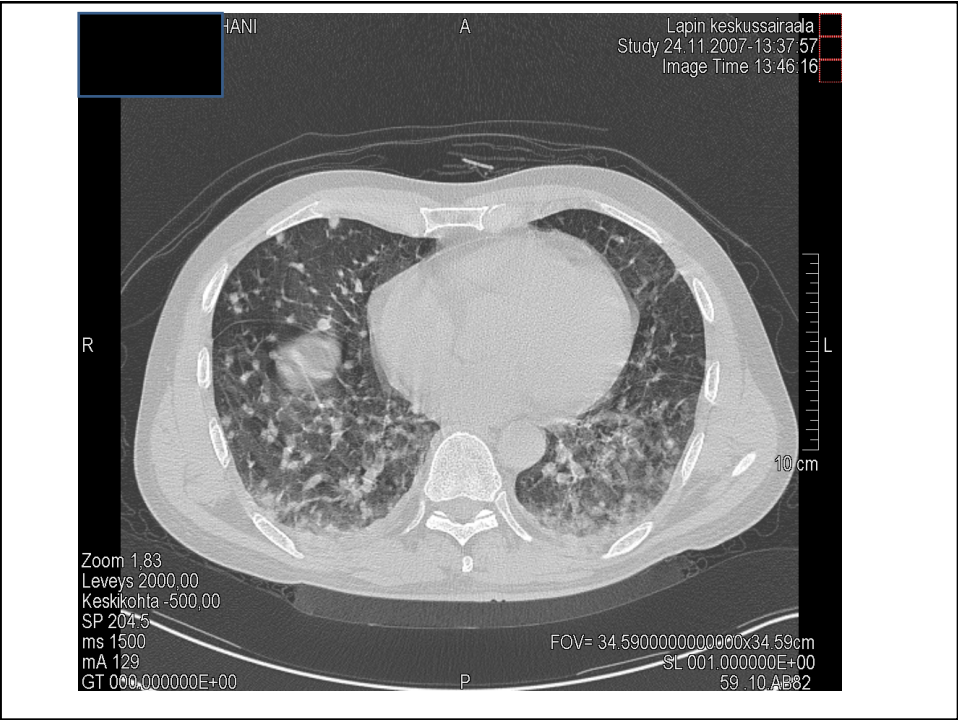
F53 xray 04.12.2007





Back to M54

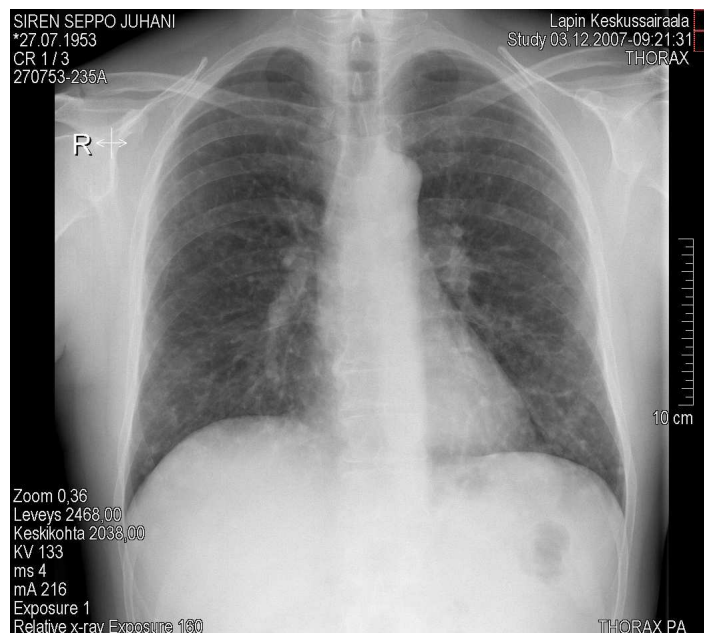- 23.11 Keftriaxone ->piperacillin-tazobactam :o
- Abd ultrasound 2x, nothing significant
- 24.11 HRCT Both lungs all over, somewhat undemarcated 5mm consolidations, some surrounded by slight ground-glass opacity some interstitial thickening, no lymphadenopathy.
- Atypical pneumonia, Legionellosis possible , allergic alveolitis and could also be.....



M54 Later

- Bronchoscopy cultures neg
- Histoplasma AB ordered, urine/serum antigen not readily available
- Sent to Karolinska inst (CF?)
- Discharged on 29.11. Legionella still a possibility levofloxacin continued for another 10 days. CRP 29 on day of discharge. Same for the others.
- Pos serology for histoplasma, coccidioides, paracoccidioides arrives on 14.12

M54 03.12.2007



- Pos histoplasma repeated 17.12
- F46 pos HPC serology 29.11 and 17.12
- M57 repeatedly negative
- F53 27.12 still negative, pos on 08.02
- Third samples of Legionella ab done, did not point to an infection.
- 14.12 all patients were improving but still had mild symptoms and xray findings. Itra not started.
- F46 still had 3mm nodules on HRCT after 1 year

- 1968 Malaysia 3% histoplasmin pos skin test v endemic areas in Americas 60-80%

Ponnampalam JT (1968) A review of histoplasmosis in Malaysia. *Medical Journal of Malaya* 22, 295-299.

- According to a textbook the vast majority of infections asymptomatic or with slight influenza like disease
- Mostly symptoms last just 2 weeks or so, longer for these
- Nitrous soil, fans in a bird house, others didn't visit
- Probably high inoculum
- Serology slow 2wk-2mo sensitivity 20-75% depending on severity
- Cultures mostly negative unless disseminated progressive
- Antigen worth it?
- Treatment, no RCT whether it reduces symptomatic period

- Itraconazole relatively non toxic, rare disease here, maybe worth it.
- Symptoms did last circa 3mo
- 200mgx3 3 d 200mg 1x2 6-12 weeks in acute pulmonary HP
- Patients got better, all is well that ends well

6-1